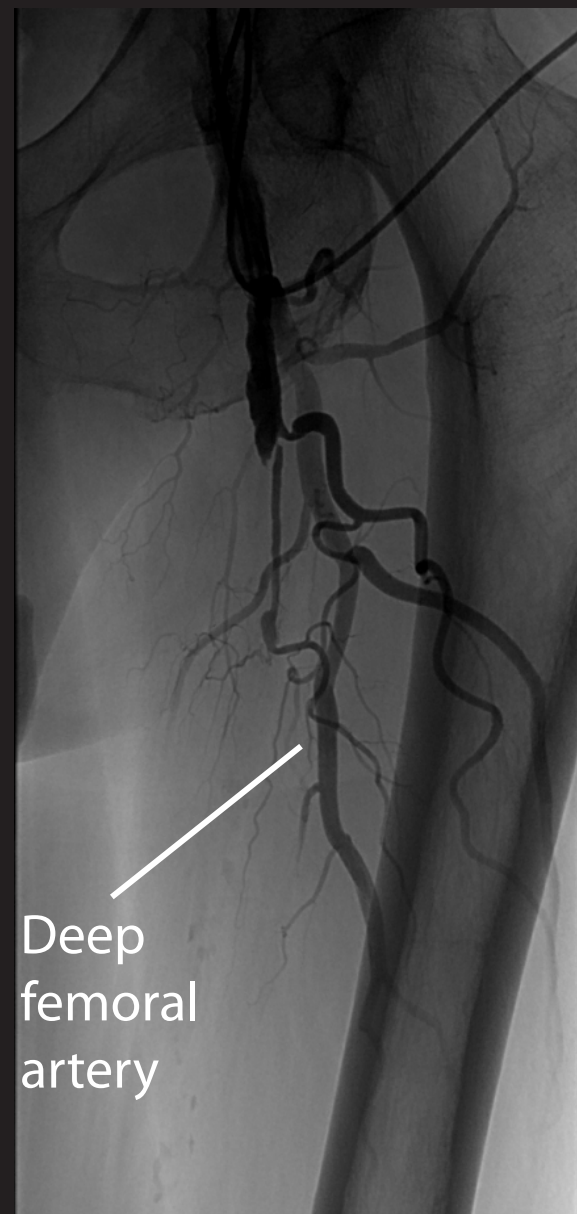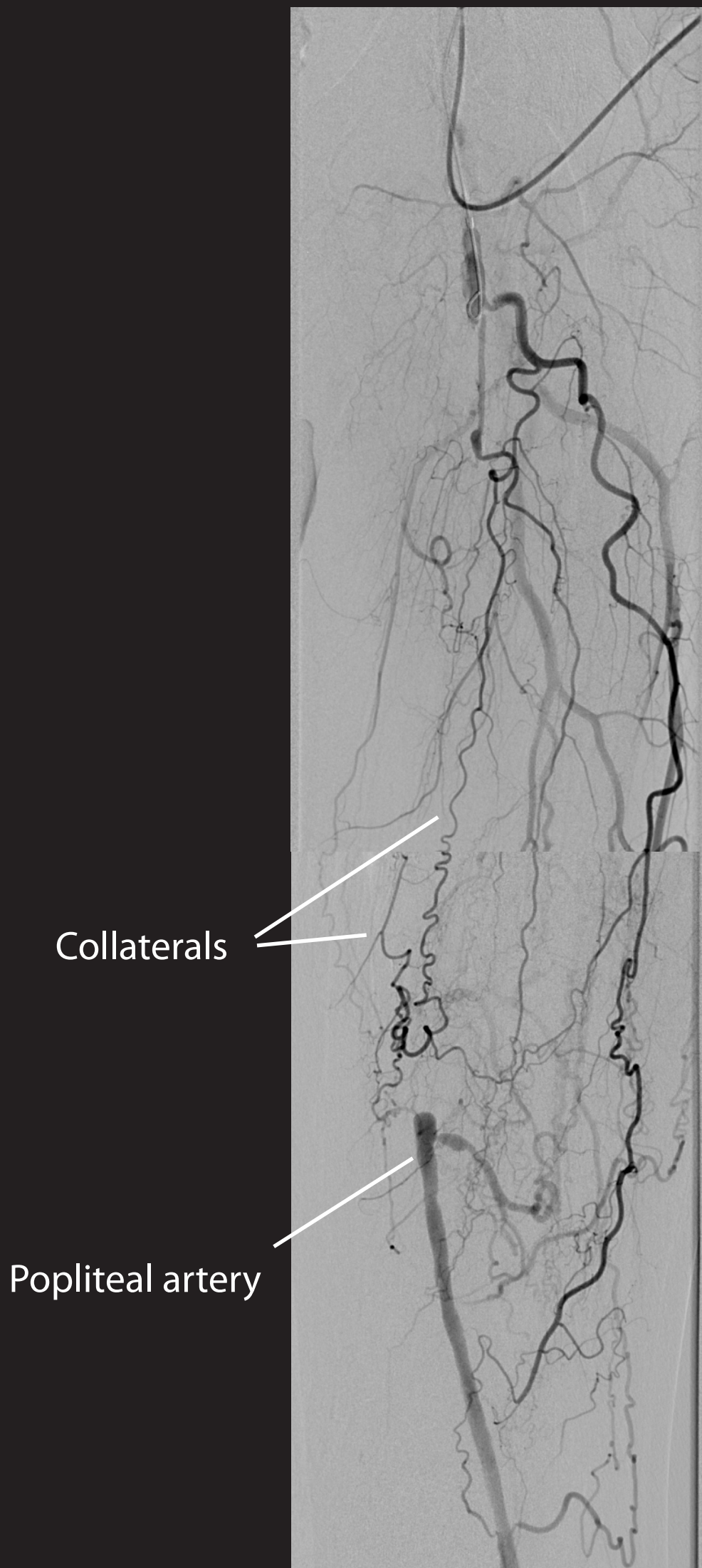


Femoral artery angiogram of a 63 year old man with intermittent claudication of the left leg. The deep (profunda) femoral artery is patent. There is a long occlusion in the superficial femoral artery from just below the bifurcation to the adductor canal. Multiple collateral arteries are visible.



Standard angiogram (above) showing patent deep femoral artery. Digital subtraction angiogram (left).